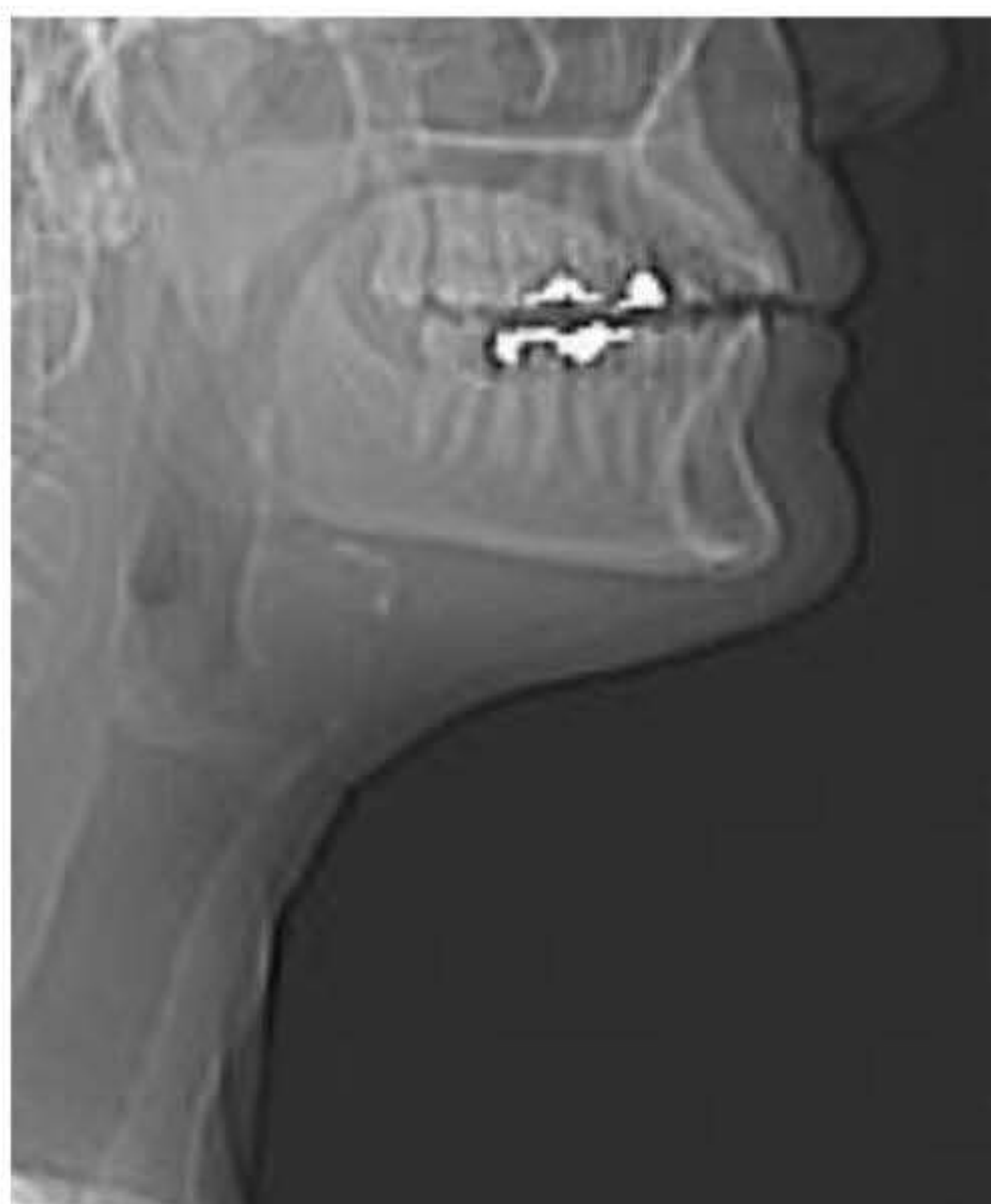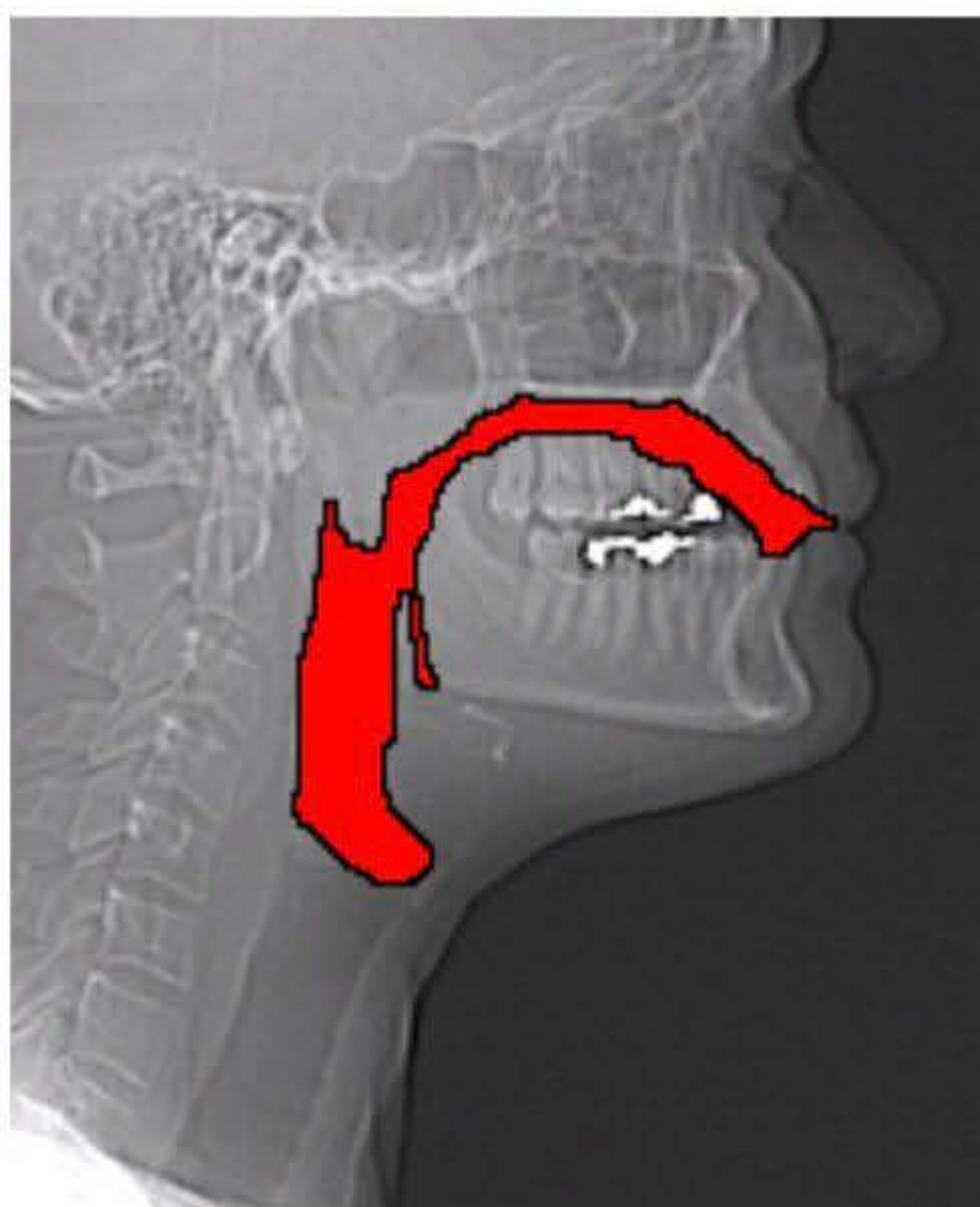
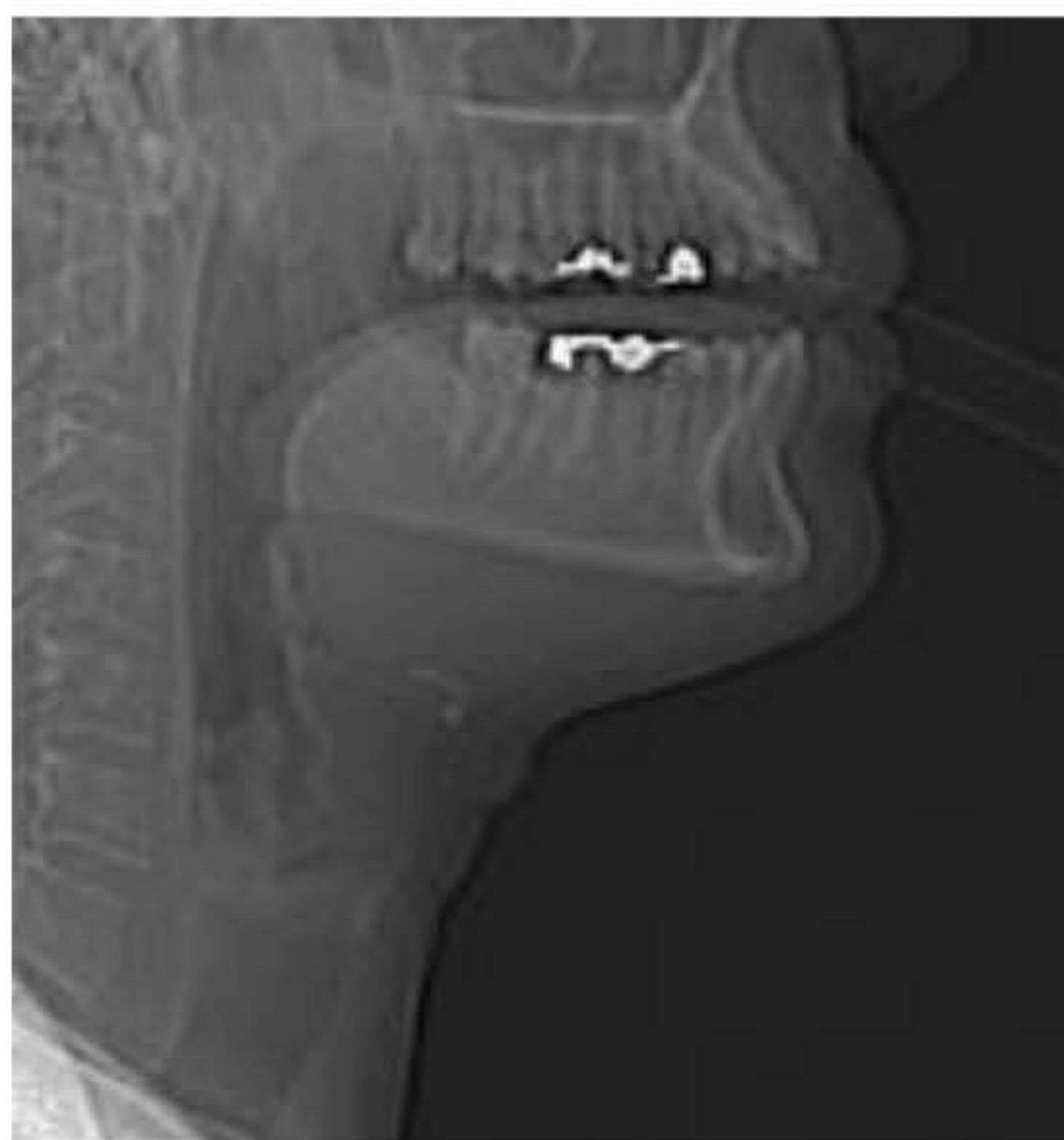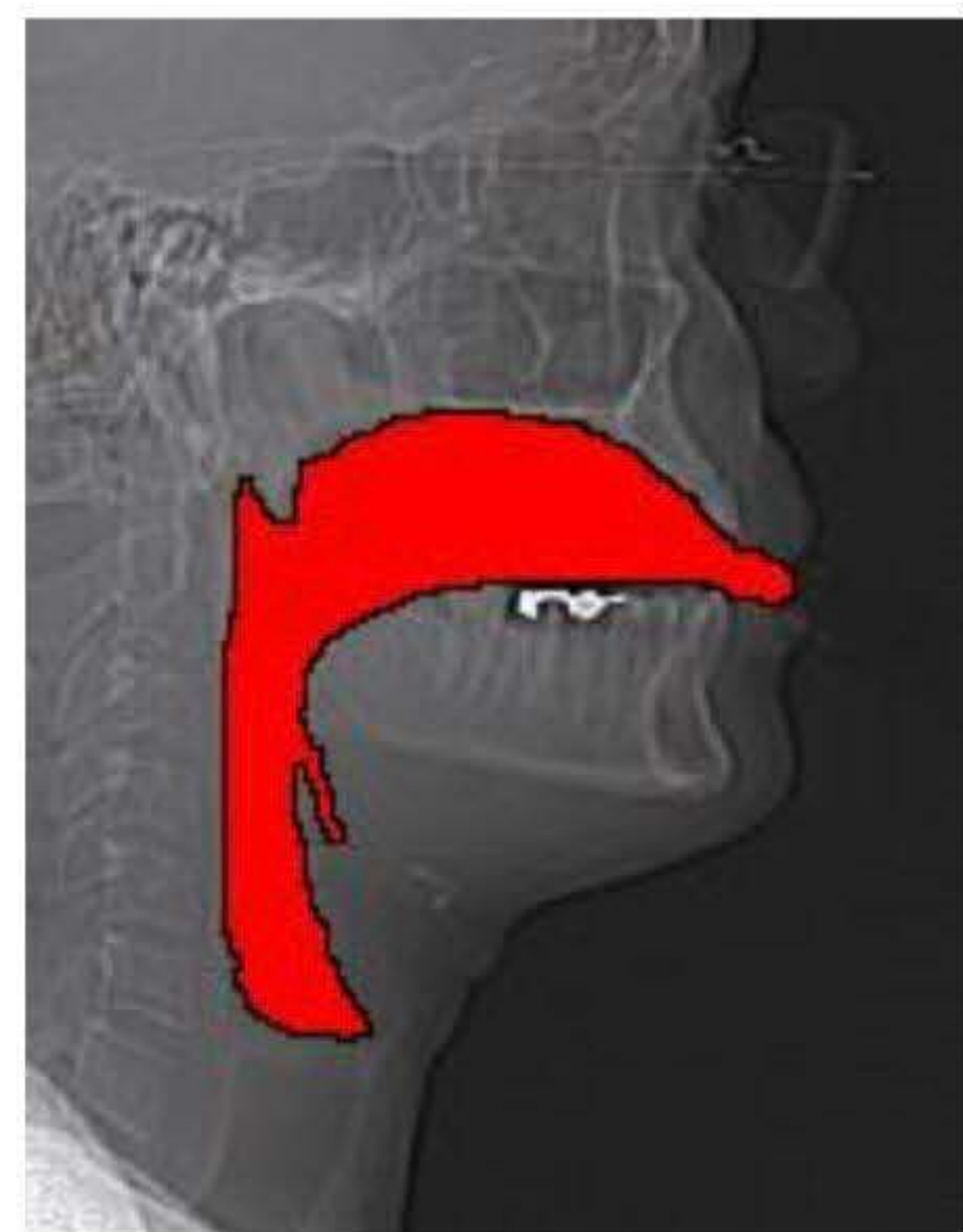


Fig. 3: Lateral tomograms showing vocal tract changes with /u/ phonation during laxvoxing



/u/ phonation without LV tube



/u/ phonation with the LV tube